SAFE Cholecystectomy: Techniques that minimize bile duct injuries

Keri Seymour, DO

August 2, 2017

Sea Pines, SC

DukeMedicine

History

- 1st laparoscopic cholecystectomy was performed by Dr Med Erich Muhe in Germany in 1985[1] and in the United States in 1988.

- In 1993, the New York State (NYS) Department of Health discovered injury to the common bile duct was 15 times higher after laparoscopic cholecystectomy (31 cases) compared to open cholecystectomy (2 cases) over a six month period

DukeMedicine

Learning curve

- Learning curve for a new technique involves increased complications and operative time, however it is the “essential precursor to success”.

- National Institutes of Health Consensus Panel on Gallstones and Laparoscopic Cholecystectomy declared outcomes were highly dependent on the skill, judgment, experience, and training of the surgeon.

- Bile duct injury occurred in 2.2% of the first 13 laparoscopic cholecystectomy cases, then decreased to 0.1%.

Since inception laparoscopic cholecystectomy is associated with increased bile duct injuries

- 750,000 cholecystectomies performed each year in US

- Laparoscopy associated with reduced pain, earlier return to activity, fewer wound infections
- 0.4% risk of biliary injury
- 2000-3000 in major biliary injury in US per year

- 3-4 per 1000 lap cholecystectomy cases
- 1 per 1000 open cholecystectomy cases

DukeMedicine

Biliary injury

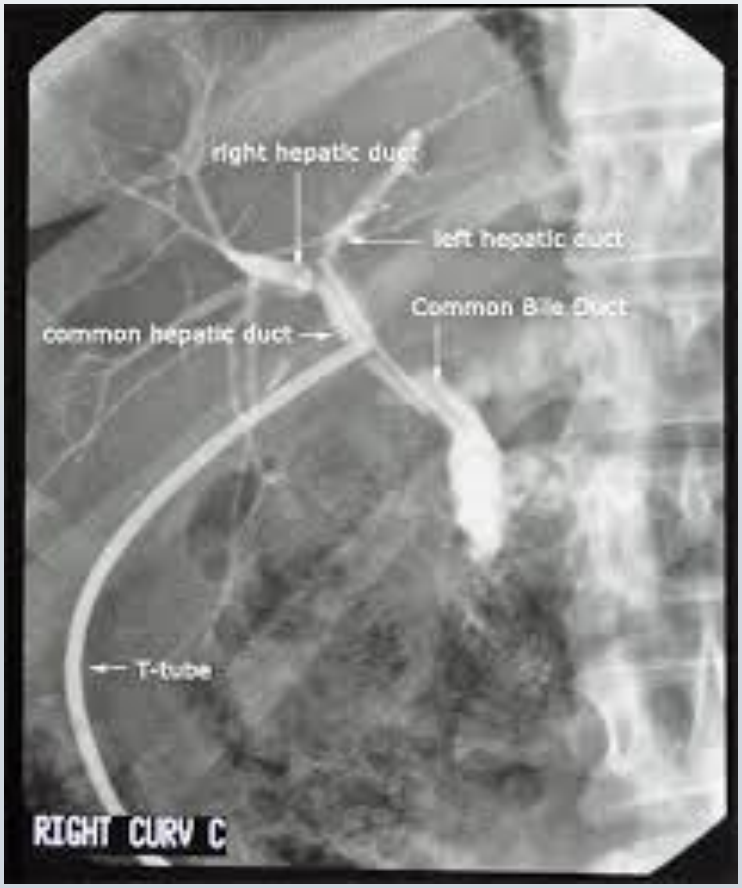

- Most major biliary injuries are due to misidentification of bile ducts, particularly, misidentification of the common bile duct as the cystic duct.
- Key concepts in pathogenesis relate to the ability of inflammatory contraction to distort biliary anatomy and the confusing effect of aberrant anatomy.

DukeMedicine

ANATOMIC VARIABILITY

DukeMedicine

Anatomic variability

- Hepatocystic triangle >Calot's triangle
- Bile duct
- Arterial anatomy
- Orienting landmarks

DukeMedicine

Calot's triangle vs Hepatocystic triangle

Calot's triangle

- In 1891 included
  - cystic duct
  - common hepatic duct
  - cystic artery (not the inferior border of the liver as is commonly believed)

Hepatocystic Triangle

- Bound by the
  - cystic duct
  - common hepatic duct
  - Liver margin

DukeMedicine

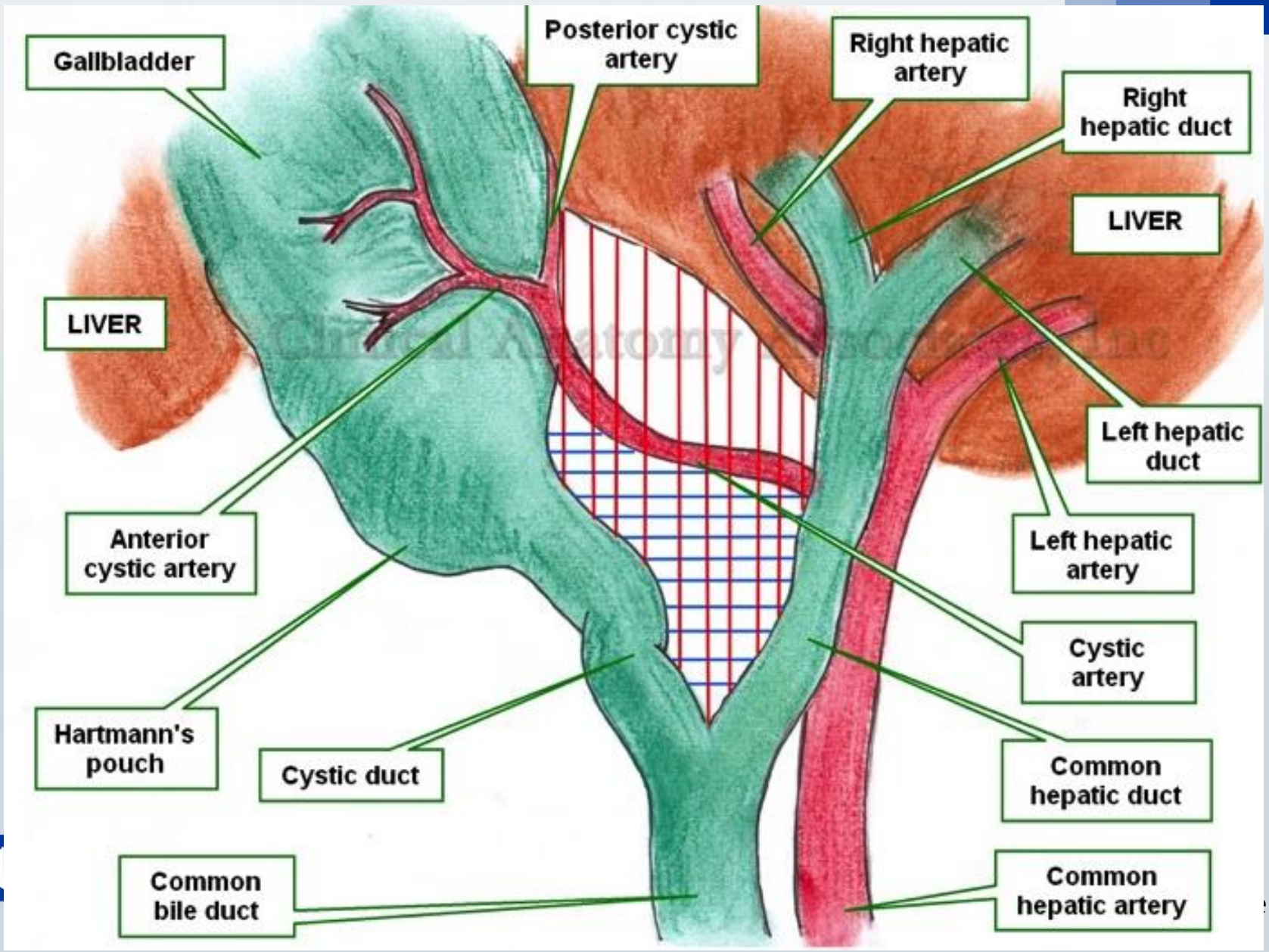
Gallbladder
Posterior cystic artery
Right hepatic artery
Right hepatic duct
LIVER
LIVER
Left hepatic duct
Anterior cystic artery
Left hepatic artery
Cystic artery
Hartmann's pouch
Cystic duct
Common hepatic duct
Common bile duct
Common hepatic artery

Cystic Artery

- Cystic artery:
  - anteromedial to cystic duct
  - inferior to lymph node

- 25% of cases the superficial and deep branch of the cystic artery have separate origins
- Deep cystic artery, as a rule,
  - arises from the right hepatic
- Superficial cystic one arises from the
  - right hepatic, middle hepatic, left hepatic, gastroduodenal, or retroduodenal

DukeMedicine

Accessary arteries

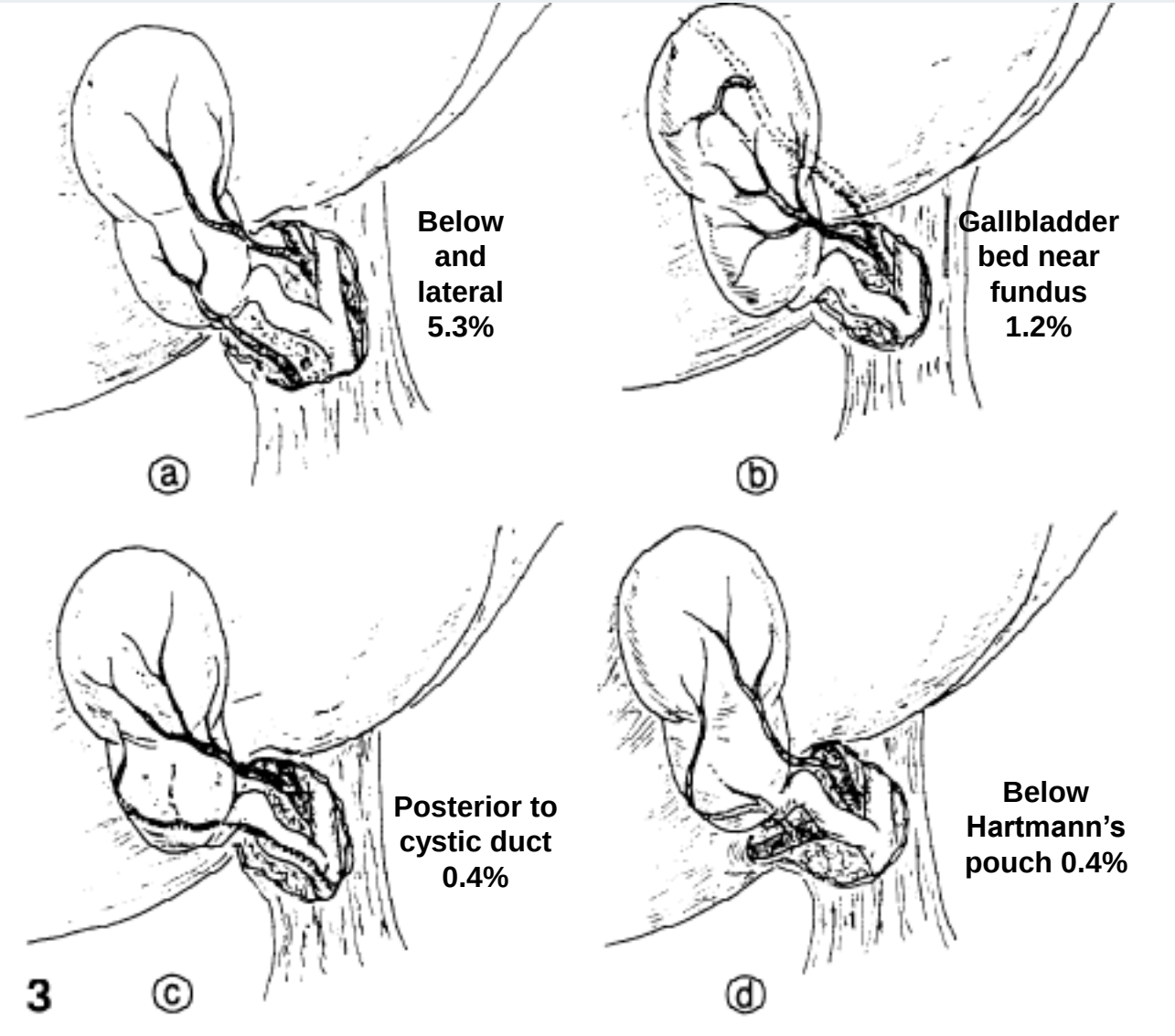

One artery is typically present in Calot's triangle but there are also accessory arteries from different origins:

a from below and lateral to the cystic duct in 5.3% of cases,

b piercing the gallbladder bed near the fundus in 1.2% of cases,

c along and posterior to the cystic duct in 0.4% of cases, and

d just below Hartmann's pouch in 0.4% of cases.

Suzuki Surg Endo 2000

No cystic artery in Calot's triangle

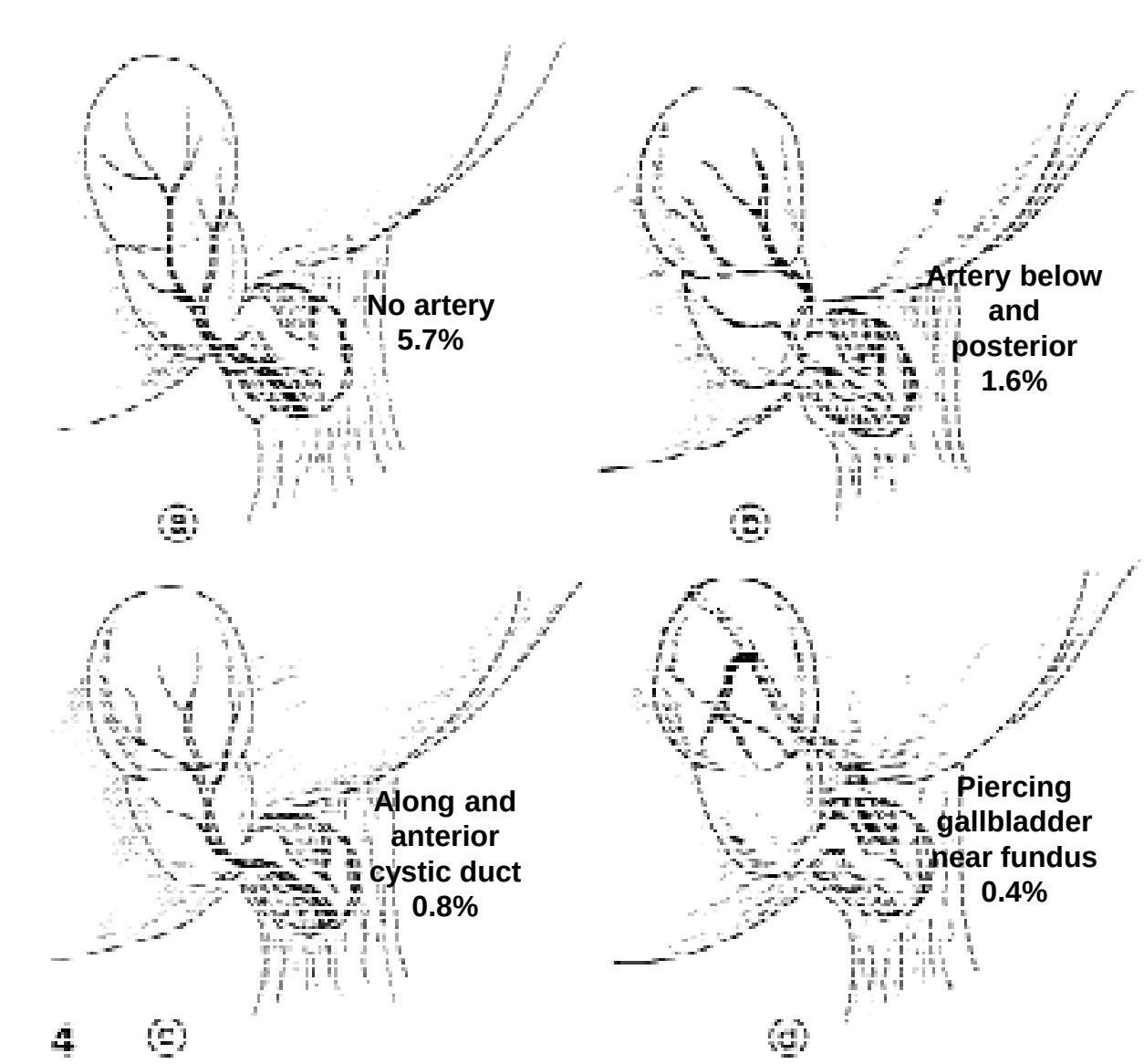

Suzuki Surg Endo 2000

Single of double artery outside of Calot's triangle

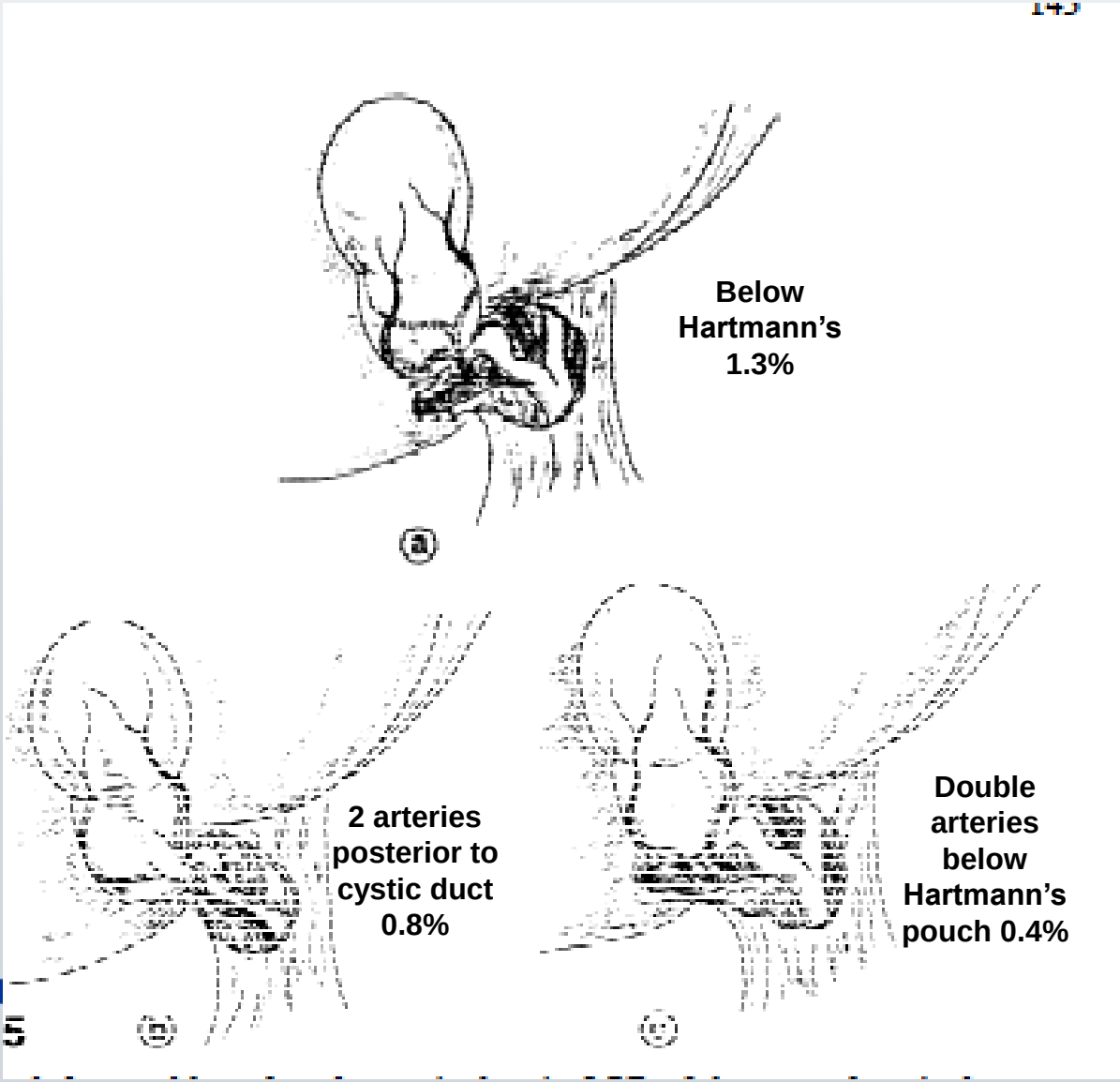

Suzuki Surg Endo 2000

Cystic Duct

- Typical anatomy of bile duct occurs in 50-60%- right anterior sectional duct 5/8+ right posterior sectional 6/7= right hepatic duct

- Most common variation when anterior and posterior do not join together-25% join left or do not join
- Low insertion right posterior duct

- 2% cystic ducts from right posterior duct, not right hepatic

- 1/3 people subvesical ducts below Glisson's capsule

DukeMedicine

Cystic duct aberrancy

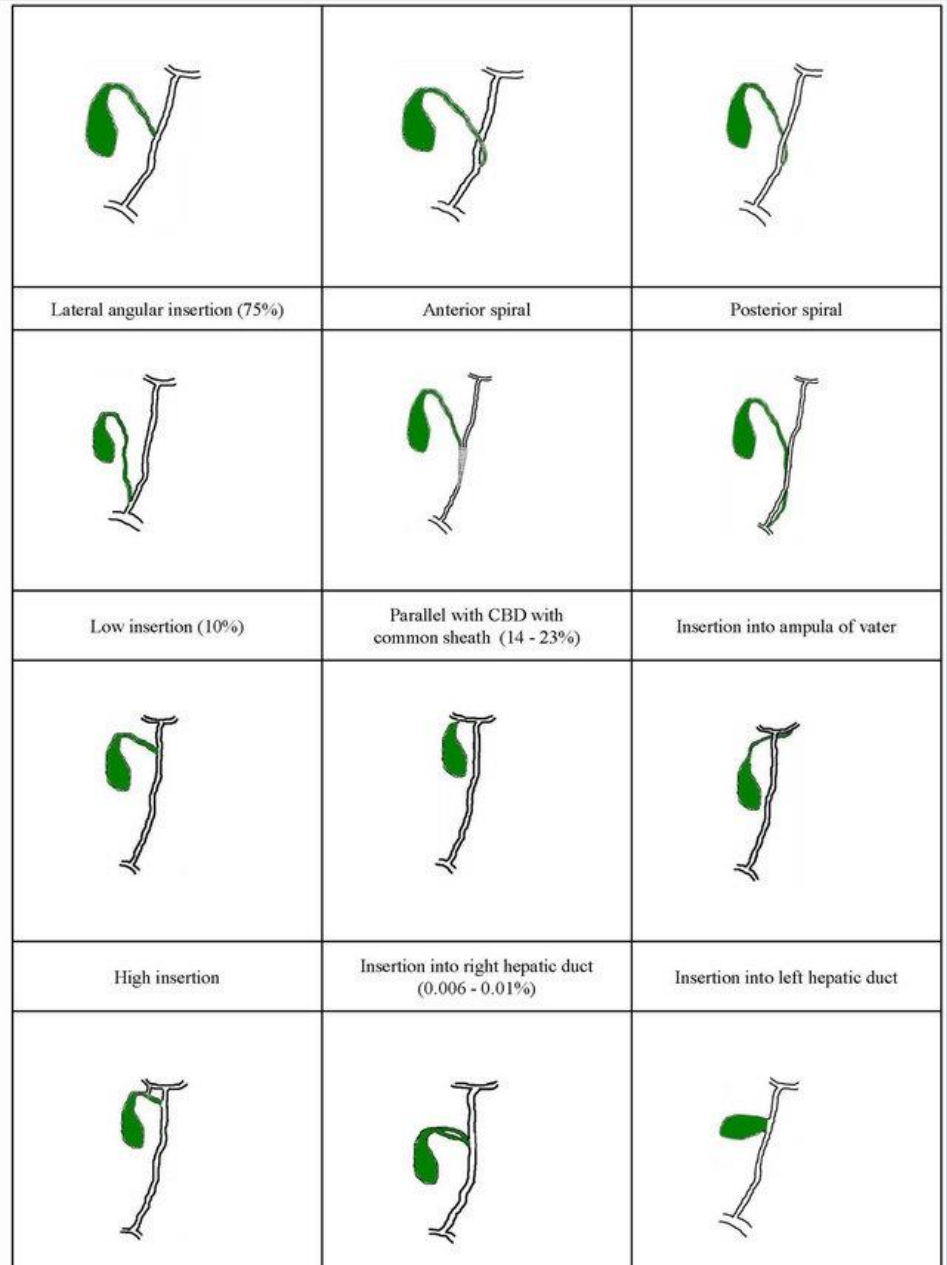

DukeMedicine

Landmarks:

- Medial:
  - Falciform between segment 3 and 4
- Superior:
  - Common hepatic duct is 4 and 5 mid plane of liver
- Posterior and Inferior:
  - Rouvieres's sulcus: fissure on right side of liver where right portal pedical enters (75-85% of pts)
- Lateral:
  - Epicholedochal plexus
- Inferior:
  - Duodenum

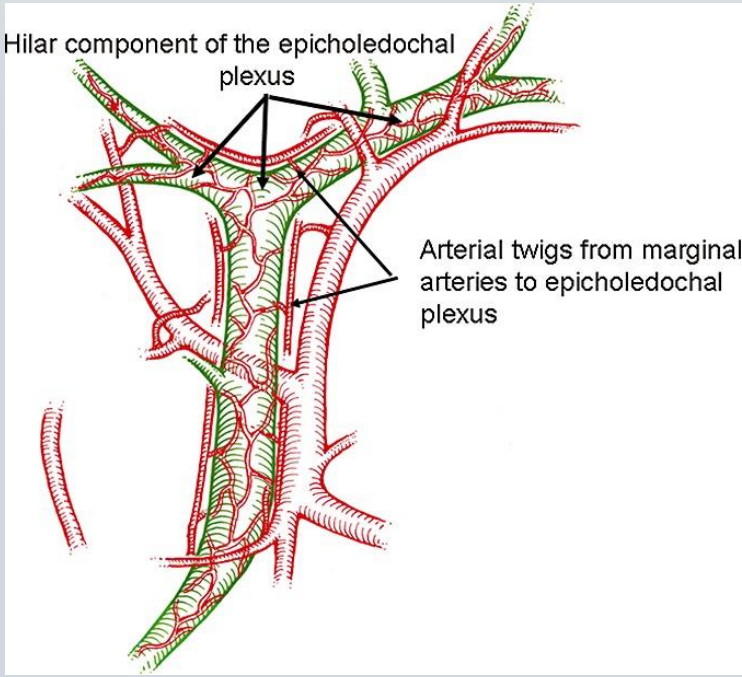

DukeMedicine

Visible CBD

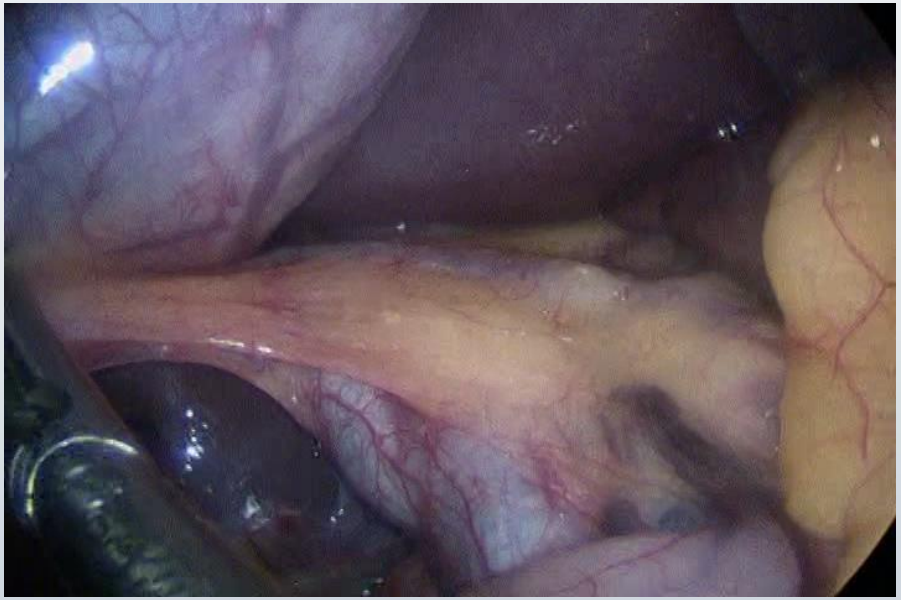

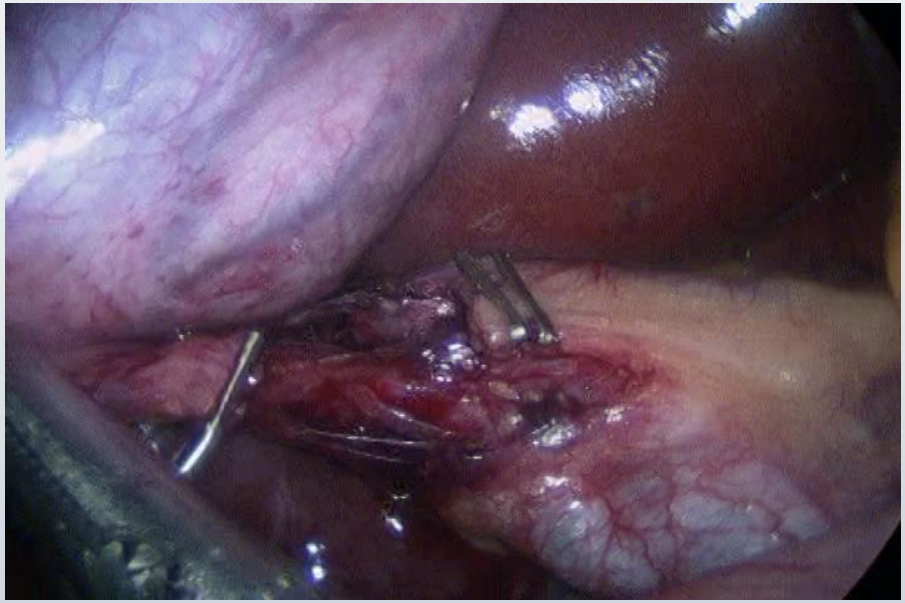

DukeMedicine

Rouvieres's sulcus:
fissure between right lobe and caudate

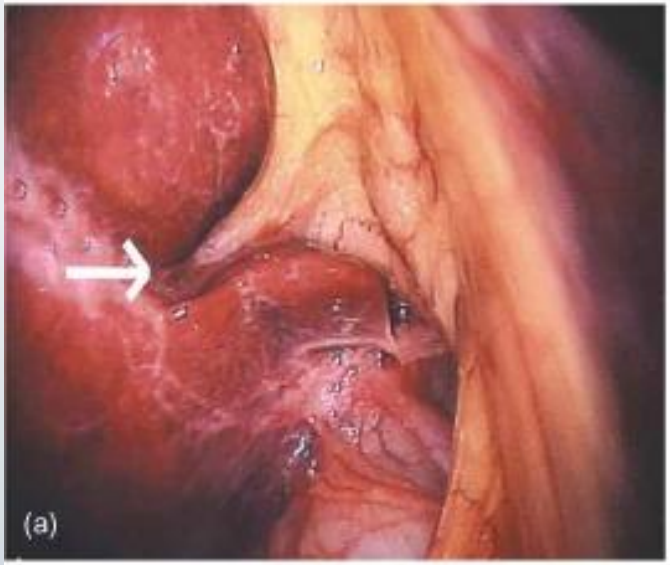

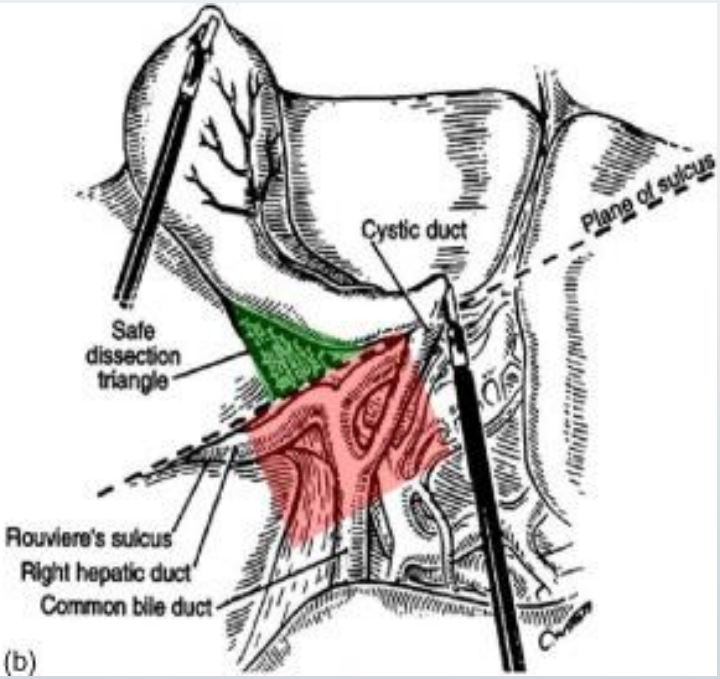

DukeMedicine

CULTURE OF SAFETY IN CHOLECYSTECTOMY

DukeMedicine

Culture of Safety in Cholecystectomy’’

- Elements such as good bail-out techniques
- good access techniques
- and other elements of safety are also employed
- Critical View of Safety,
- routine cholangiography,
- the infundibular technique,
- visualization of the common bile duct and common
- hepatic duct, and
- top-down cholecystectomy are some methods

DukeMedicine

6 suggested strategies for Safe Cholecystectomy

- Critical View of Safety
- Intraoperative timeout to confirm CVS prior to clipping
- Understand aberrant anatomy
- Imaging of biliary tree
- Stop before entering zone of significant risk
- Ask for another surgeons assistance

DukeMedicine

Infundibular Technique

- Funnel-shape
  junction is ide
- Easier to ach
- Biliary inflam
  contraction ca
  the cystic duc
- Increases the

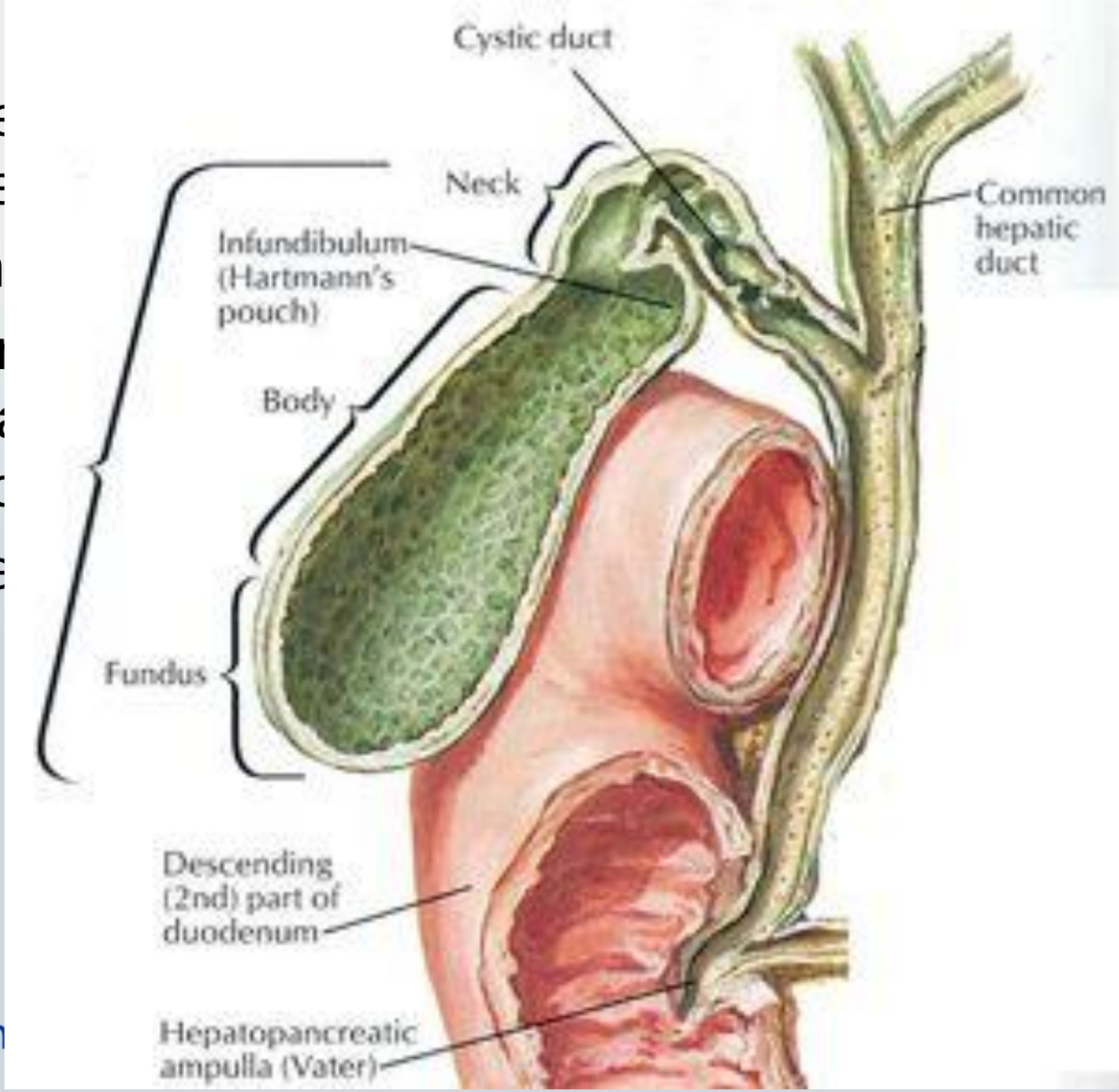

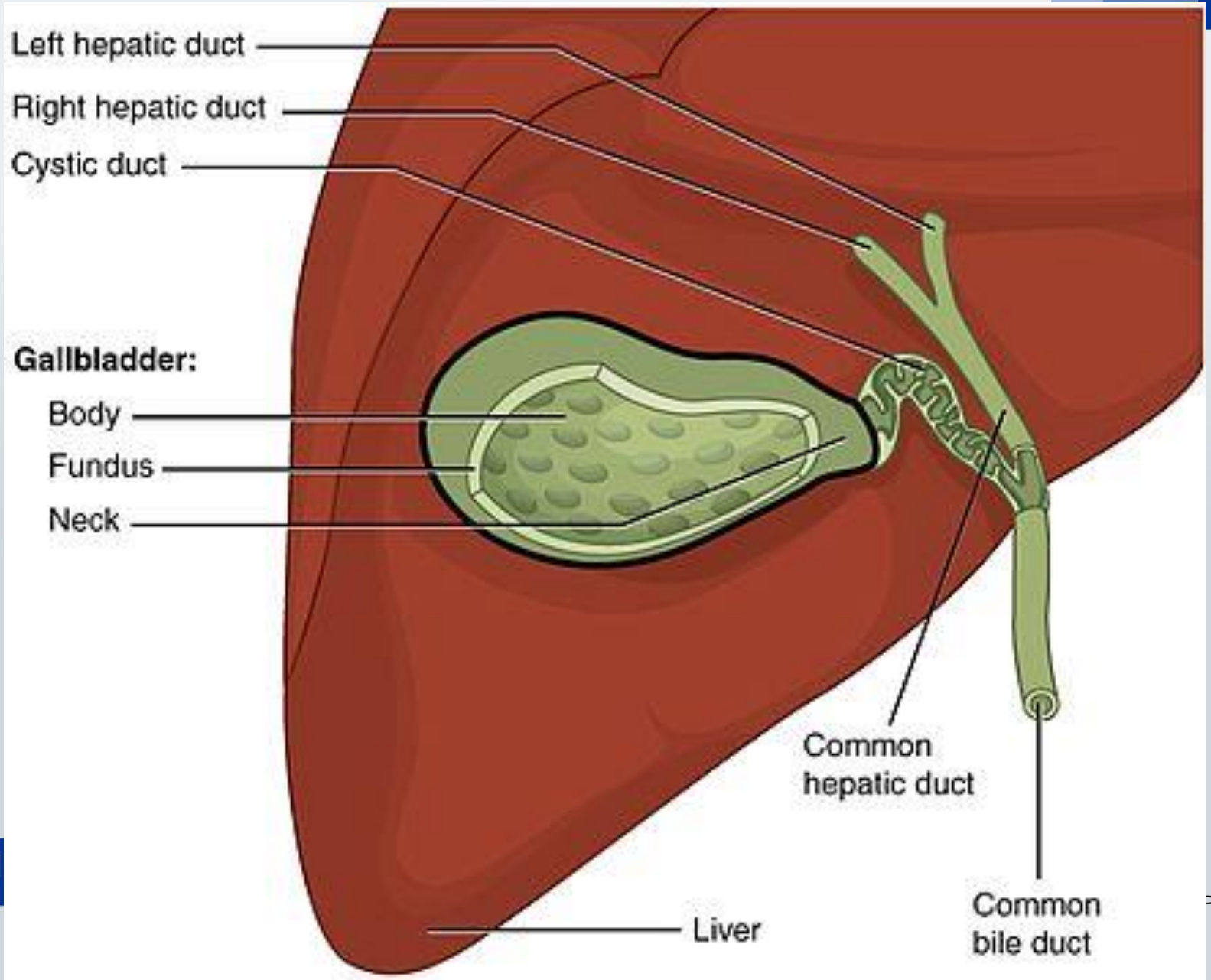
Left hepatic duct
Right hepatic duct
Cystic duct
Gallbladder:
Body
Fundus
Neck
Common hepatic duct
Common bile duct
Liver

1-Critical View of Safety

- Introduced by Strasburg in 1995
- Used to identify the cystic duct and cystic artery
- Three components
  1. Clear the hepatocystic triangle of fat and fibrous tissue
  2. Cystic plate is exposed by separating lower 1/3 of gallbladder from liver
  3. Only 2 structures enter the gallbladder

DukeMedicine

"Critical View of Safety"

- Introduced in an analytical review written in response to the sudden increase in biliary injury associated with laparoscopic cholecystectomy.
- CVS is a modification from open cholecystectomy
- in which the cystic duct and artery are putatively identified after completely removed from the cystic plate and attached only by the 2 cystic structures.
- Only then is secure target identification achieved.
- In laparoscopic surgery, complete separation of the gallbladder from the cystic plate makes clipping of the cystic structures difficult, so this step was modified to require only that the lower part of the gallbladder (about one-third) be separated from the cystic plate

The Critical View

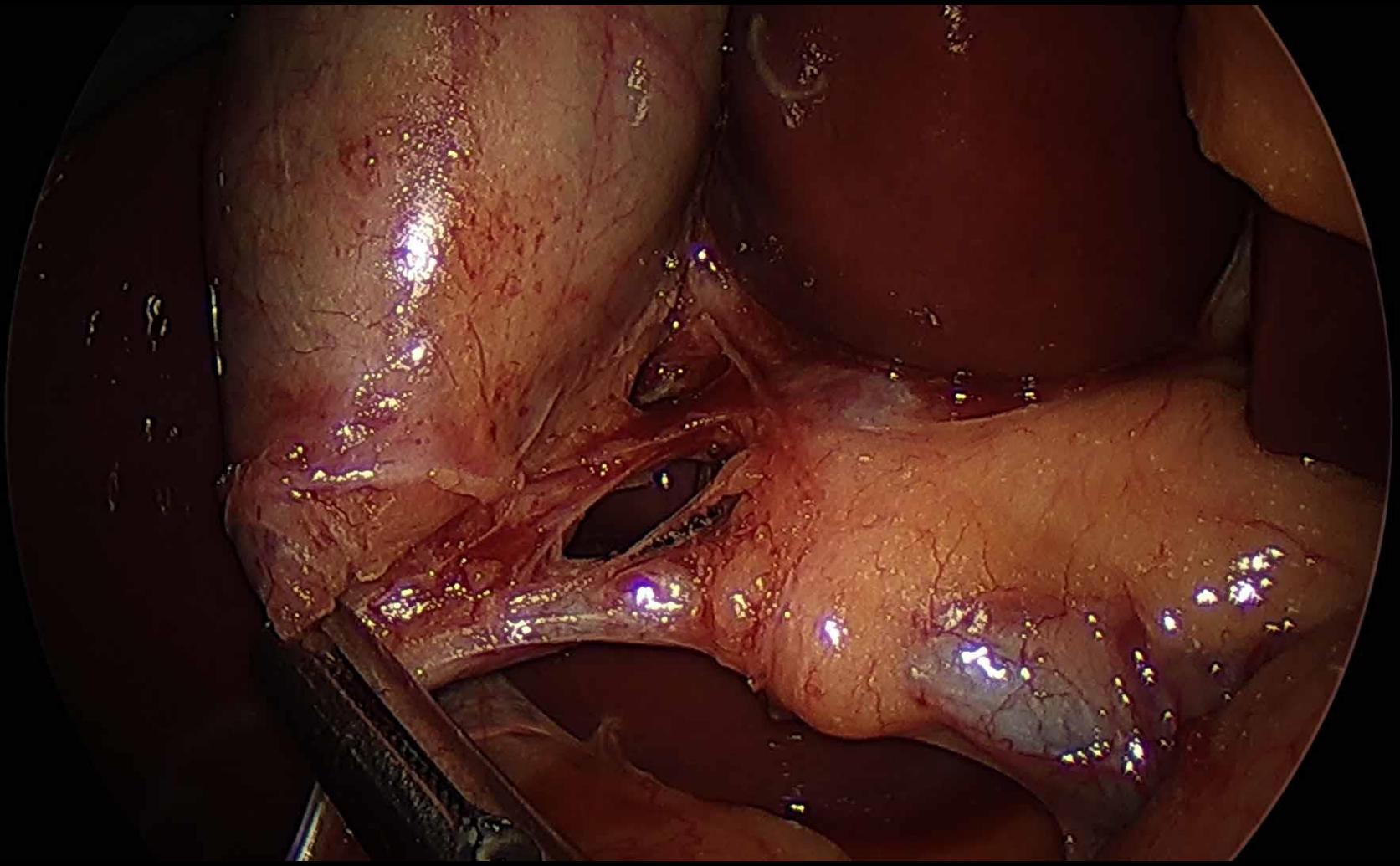

2-Time out

- Intraoperative timeout to confirm CVS prior to clipping
- Use the doublet view

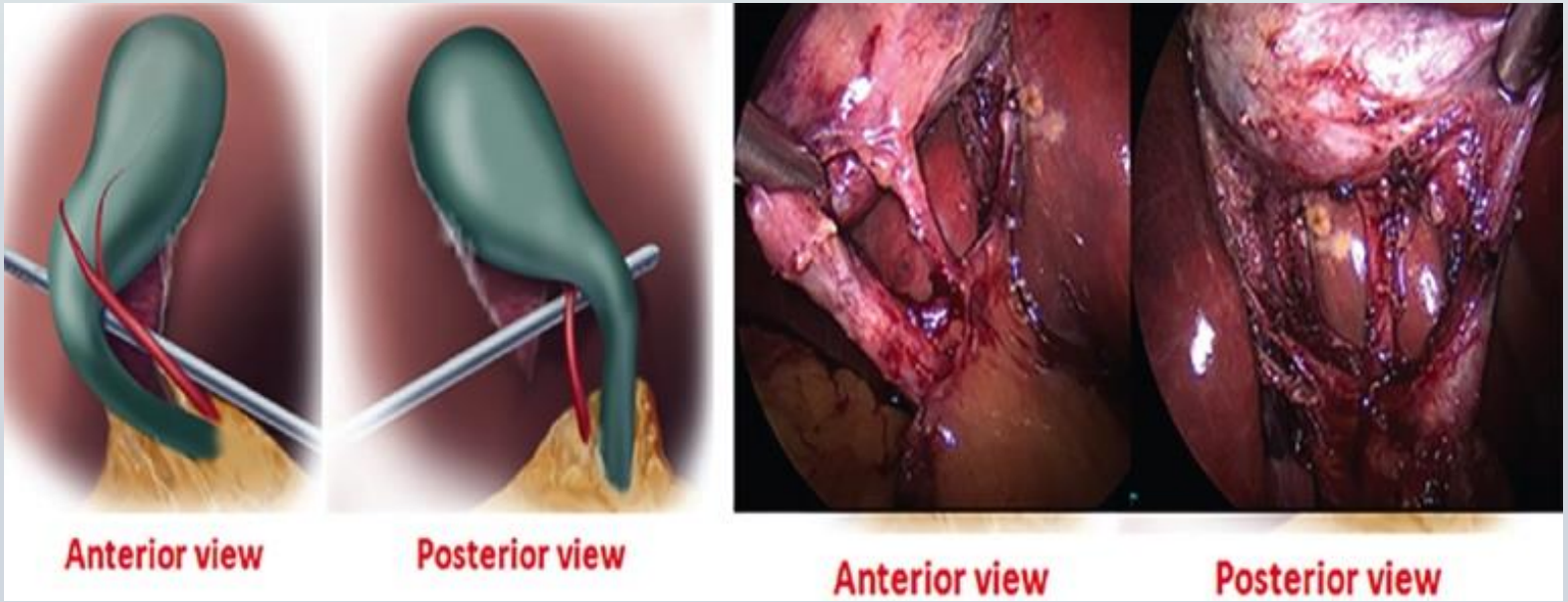

DukeMedicine

The Critical View (after clips placed)

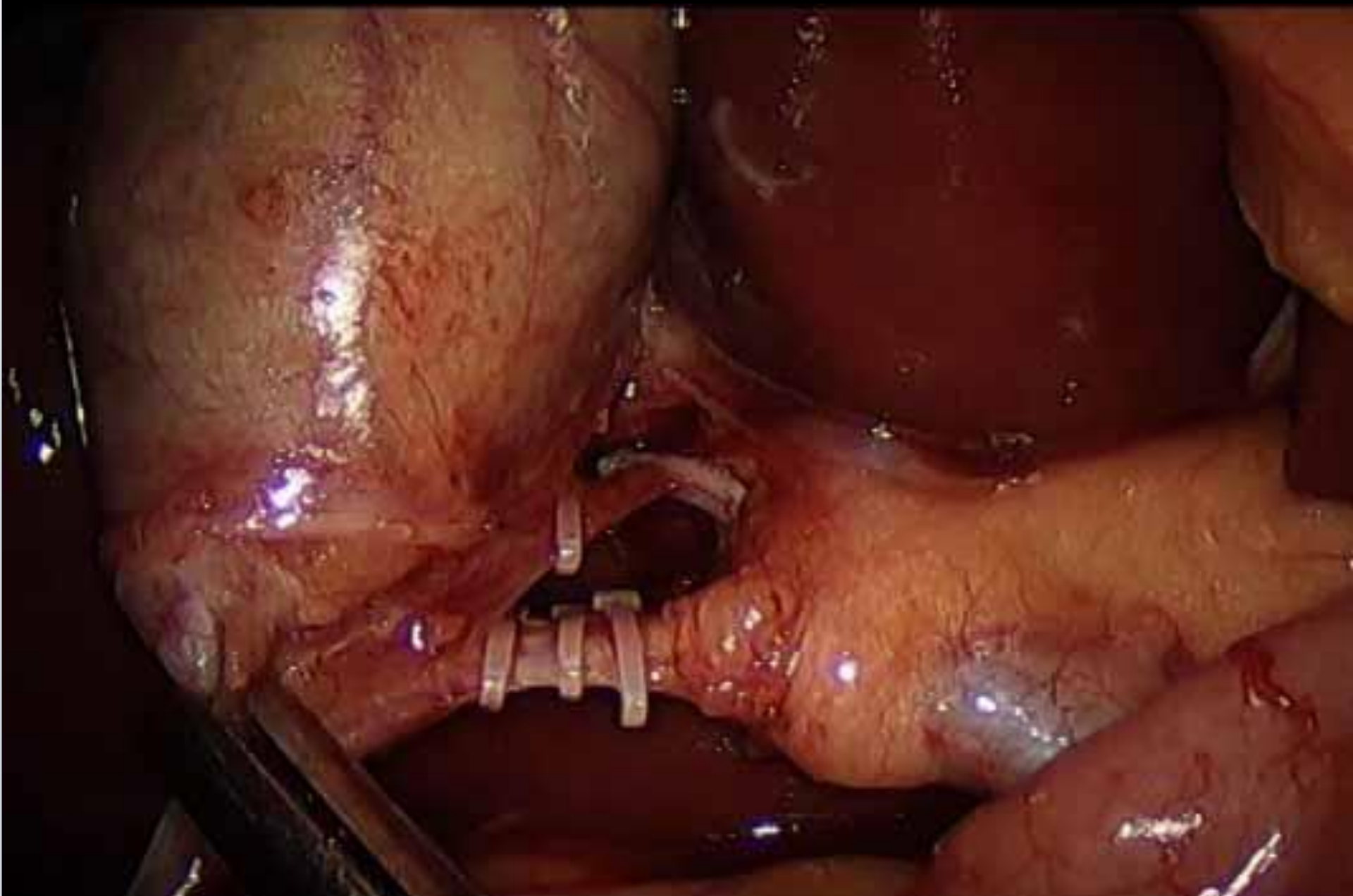

3-Aberrant Anatomy

- Short cystic duct
- Aberrant hepatic duct
- Artery:
  - 75% single artery: superficial and deep branch
  - From R hepatic artery
    - 25% multiple cystic artery
    - 30% alternative source
    - 10-15% source outside hepatocystic triangle

DukeMedicine

4-Image biliary tree

- Liberal use of cholangiogram
- Define anatomy
- Difficult cases

- Consider ICG imaging

DukeMedicine

Cholangiogram

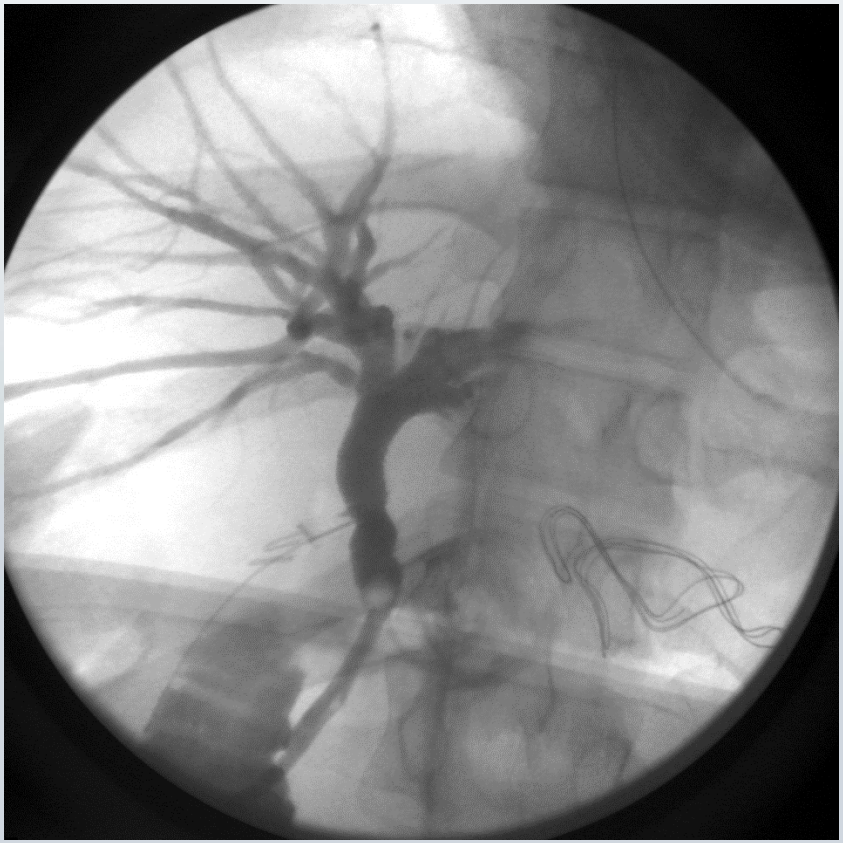

- Performed selectively (anatomy vs CBD stone)
- 3-5% chance stone in CBD
- Technique:
  - Visualize left and right hepatic ducts
  - Visualize contrast entering duodenum
- Pitfalls:
  - Occlude catheter (metal clips)
  - No bubbles (withdraw don’t push)
  - May need to place pt in Trendelenburg

DukeMedicine

Intra-operative cholangiogram

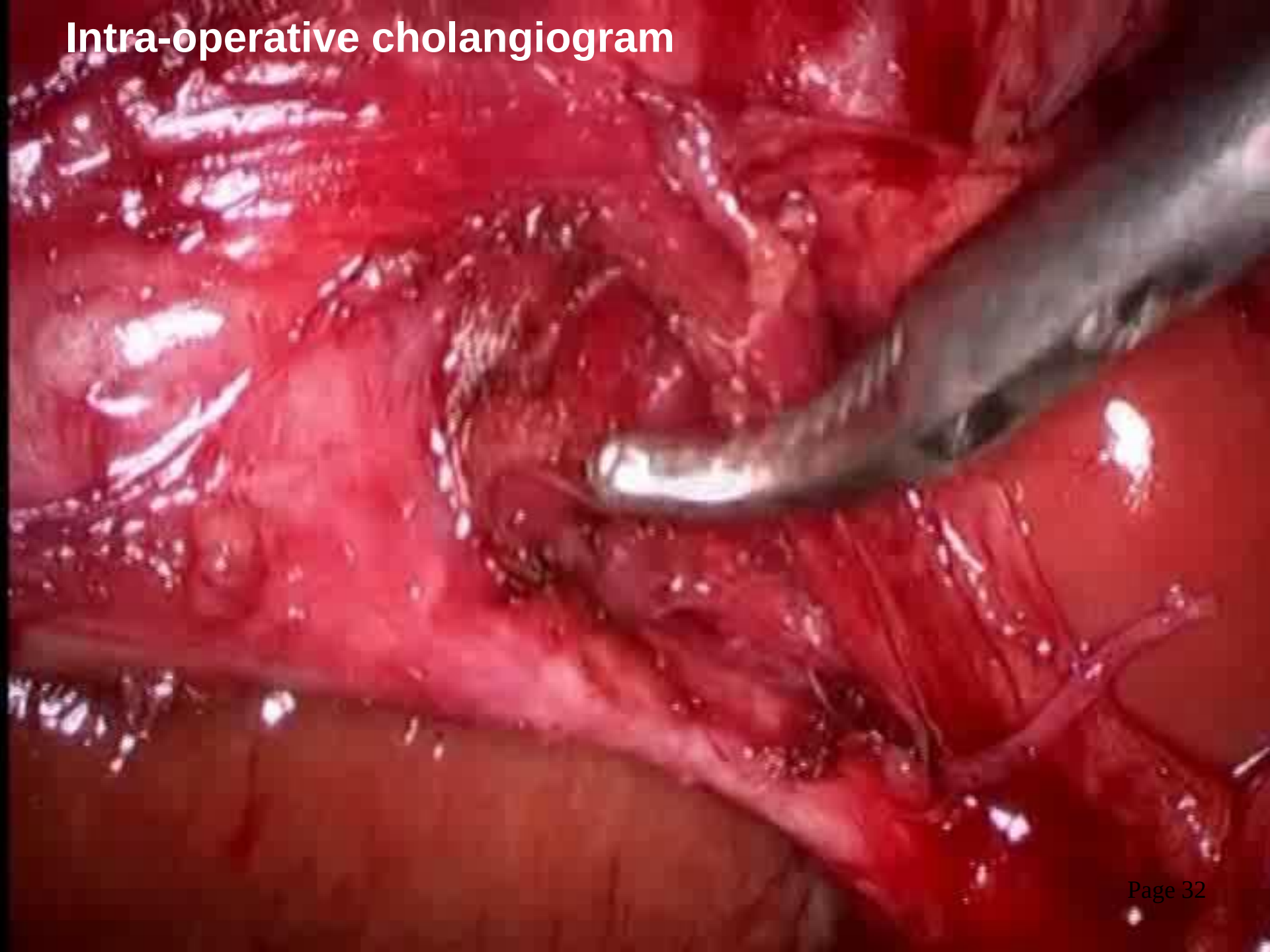

5- Stop surgery when dissection is too difficult

- Recognize zone of significant risk
- Stop before entering this area
- If CVS is not able to expose than stop surgery (subtotal vs tube vs open)
- If unable to identify hepatocystic triangle
- Dissection is not progressing
- Excessive bleeding
- Extensive fibrosis

DukeMedicine

Safe Bailout
Damage Control Techniques

- Drainage:
  - Leave a cholecystostomy tube: return in 3 months
- Fundus-first approach
  - Dissection starts from fundus to infundibulum
  - Goal is better identification of Calot triangle structures
  - Be careful of dissecting too far
- Subtotal cholecystectomies
  - Fenestrating
  - Reconstituting

DukeMedicine

Cholecystostomy tube

- Cholecystostomy decompresses severely inflamed or GB empyemas
- Bridge toward definitive treatment

- Technique
  - Placement of a ‘‘purse-string’’ suture
  - Gallbladder fundus entered
  - Contents suctioned
  - Drainage catheter brought through the abdomen wall (‘‘mushroom tip’’ catheter or Foley balloon catheter) is placed into the gallbladder lumen.
  - Definitive cholecystectomy in 2–3 months

Subtotal

- 1st reported by Madding in 1955
- Replacement for cholecystostomy
- Rescue procedure in cases of technically difficult total cholecystectomy

- Technique
  - Incising the GB at the fundus
  - Carried down to 1 cm from the CD
  - Excising the redundant GB wall
  - Piecemeal excision of the GB
  - Mucosa of remnant was coagulated or left intact
  - CD was closed from within the GB with a purse-string suture

DukeMedicine

Elshaer JAMA Surg 2015

Subtotal Cholecystectomy (not partial)

- Removes portions of the GB when the structures of the Calot triangle cannot be identified and the critical view of safety cannot be achieved.

- Technique:
  - Longitudinal incision on gallbaldder away from infundibulum
  - Remove all stones
  - Suture close cystic duct if bile leaking
  - +/- Imaging
  - Fulgurate posterior wall of gb
  - Leave closed suction drain

DukeMedicine

Elshaer JAMA Surg 2015

Complications from Subtotal Cholecystectomy

- Morbidity rates were relatively low
  - postoperative hemorrhage 0.3%
  - subhepatic collections 2.9%
  - bile duct injury 0.08%
  - retained stones 3.1%

- Rate for bile leaks was higher (18.0%)

- CBD injury was absent in the subgroup in which the CD or GB stump was left open because of avoidance of the hazardous dissection of the CD in cases with difficult Calot triangles

DukeMedicine

Types of Subtotal Cholecystectomy

Fenestrating

- Does not occlude the gallbladder
- May suture the cystic duct internally
- Higher incidence
- of postoperative biliary fistula
- Not associated with recurrent cholecystolithiasis

Reconstituting

- Closes off the lower end of the gallbladder
- Reducing the incidence of postoperative fistula
- Creates a remnant gallbladder
- May result in recurrence of symptomatic cholecystolithiasis

DukeMedicine

Subtotal Fenestrating Cholecystectomy

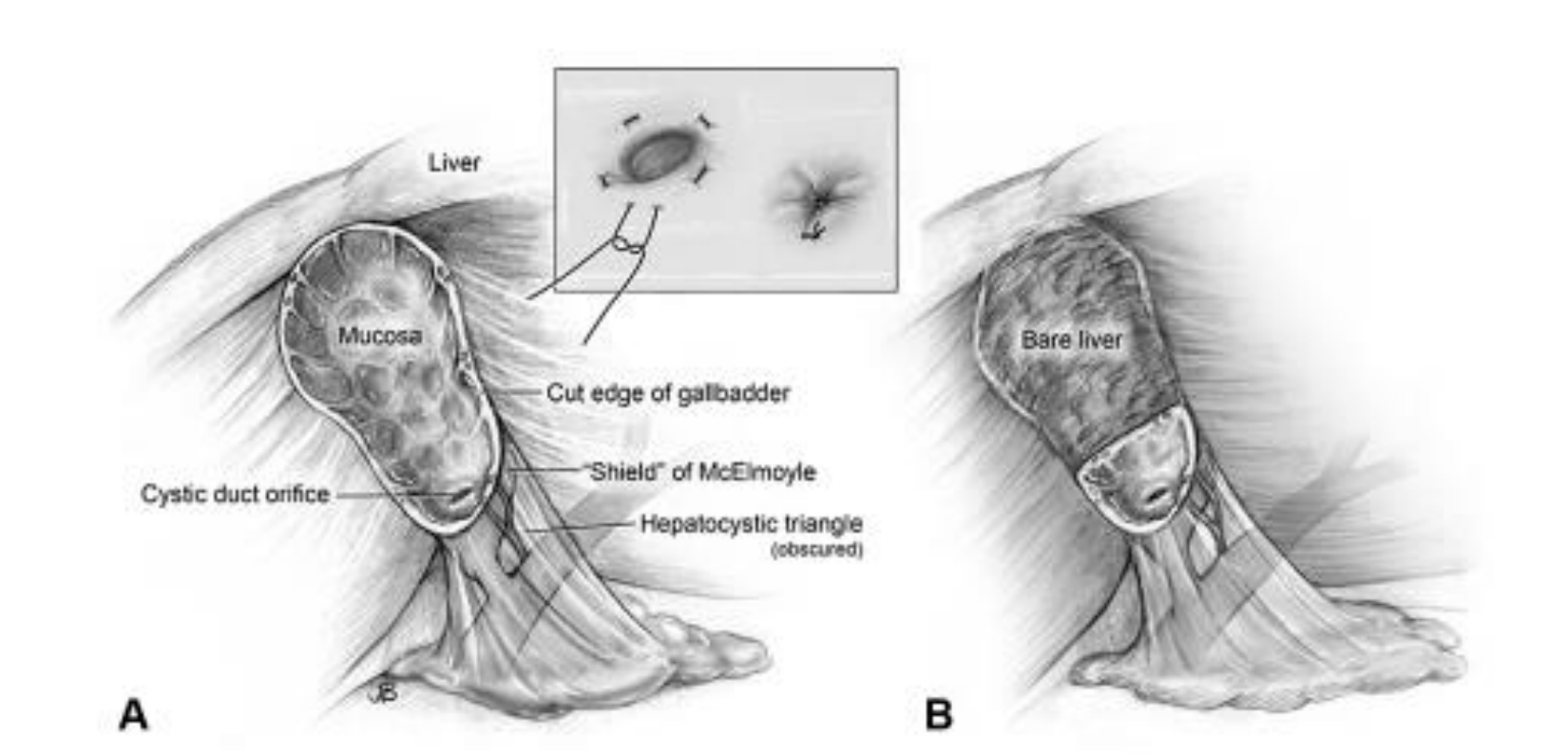

DukeMedicine

Subtotal Reconstituting Cholecystectomy

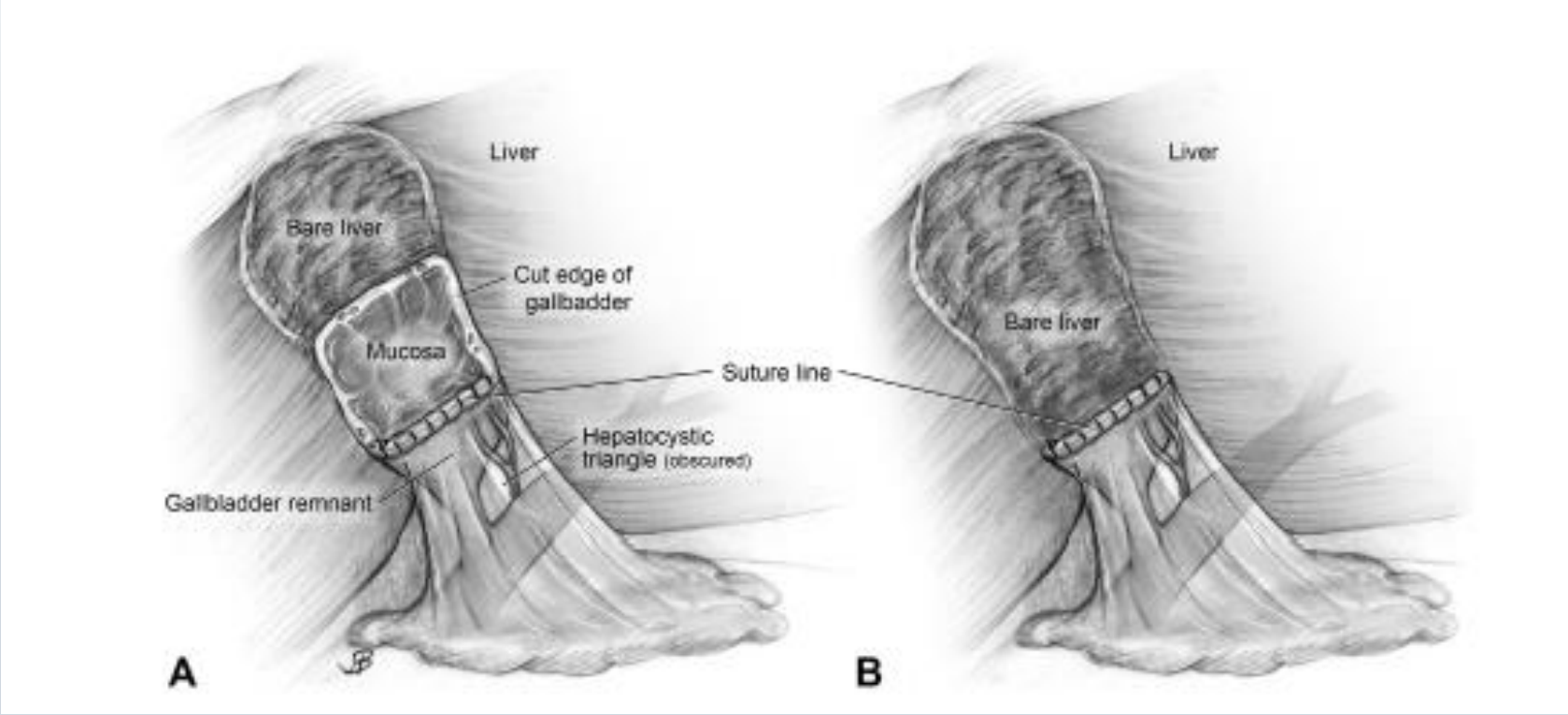

DukeMedicine

Remnant Gallbladder

- gallbladder remnants may
  require excision in a seco
  shortly after the initial ope
- The latter is an important
  publications dealing with t
  complete cholecystectom
  times and therefore, may
  consequences of leaving
- Furthermore, operations t
  may be difficult, so proced
  remnant gallbladders are more desirable than those that do

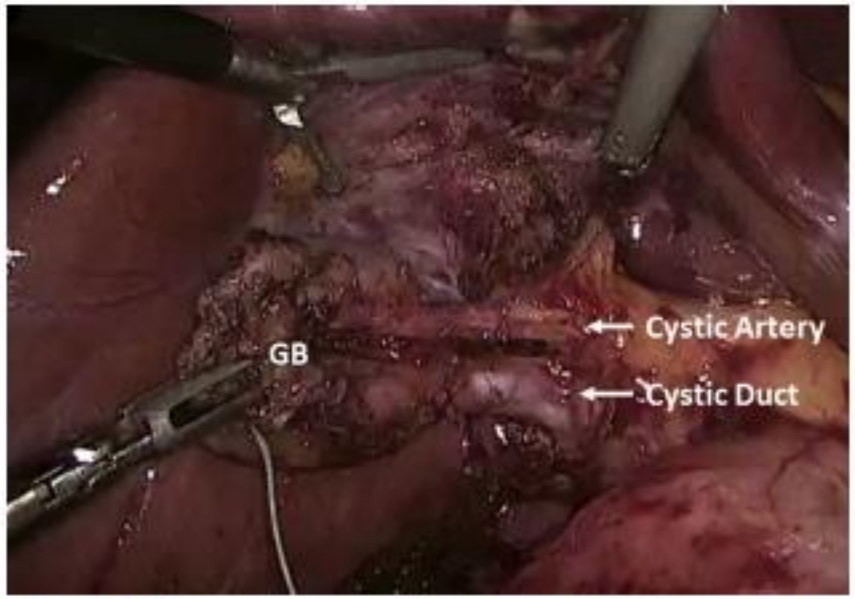

Figure 4. Intraoperative photograph at conclusion of laparoscopic dissection to free a remnant gallbladder (GB) in a patient who had become symptomatic after a previous subtotal cholecystectomy.

DukeMedicine

6-Ask for help from another surgeon

- Helpful for a second opinion when
- Dissection is stalled
- Anatomy is unclear
- Surgery has become difficult for primary surgeon

DukeMedicine

Laparotomy

- Indications:
  - Bleeding
  - Lack of progress
  - Need for tactile feedback
- Call for help

- Technique
  - Start as subtotal
  - Large incision
  - Packs to elevate liver
  - Self retaining retractors
  - Head light

- Cystic plate retracts and injury to portal vein

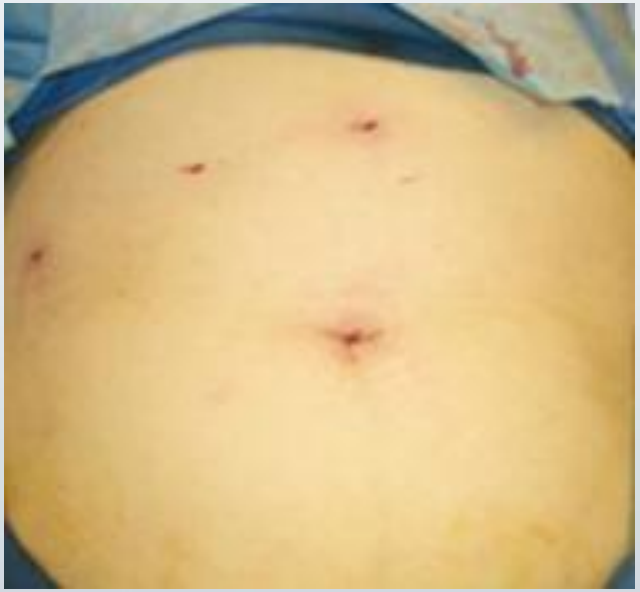

DukeMedicine

Advanced instruments

- Add extra ports
- 10mm suction catheter
- Advanced energy device: ultrsonic shears?
- Get the best optics : increase to 10mm scope
- Place liver bar
- Bring in laparoscopic needle drivers

- Argon
- More endocatch bags

DukeMedicine

DIFFICULT GALLBLADDER

DukeMedicine

Non-surgical options

- Stone-dissolving medication (ursodiol / Actigall)
  - expensive (need to take it for life)
  - may not work on larger stones
  - side effects include diarrhea and abdominal pain

- Break up the stones (lithotripsy)
  - not offered in most places
  - stones will re-form

DukeMedicine

Benefits of surgery

- To get rid of symptoms.
- To minimize risk of other complications of gallstones – **cholecystitis, cholangitis,** and **pancreatitis**.

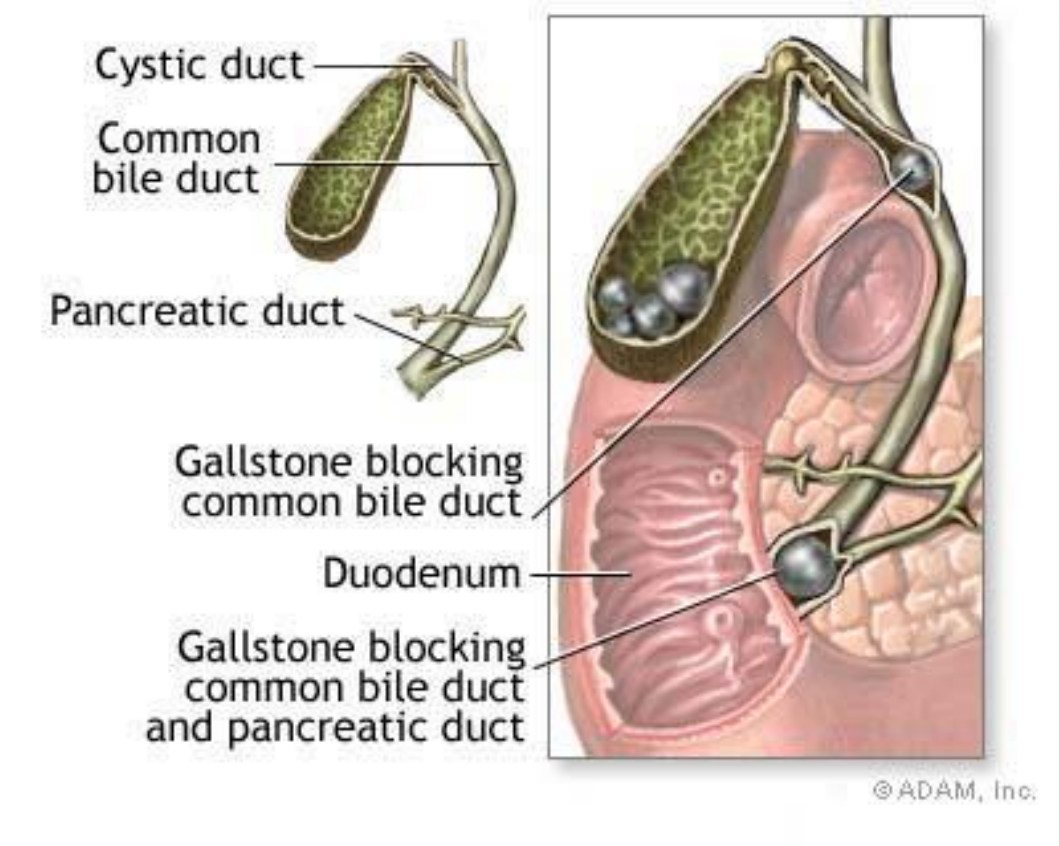

DukeMedicine

Risks of surgery

- Conversion to an open procedure – 1% for elective (as high as 29% in urgent situations)
- Bile duct injury (0.2%)
- Bile leak (2%)
- Retained stone in the common bile duct
- Diarrhea

- Persistent symptoms after surgery
- Infection (intra-abdominal, wound, lungs, bladder)
- Blood clot in major vein in legs and/or lungs
- Bleeding
- Heart attack
- Stroke

Difficult Gallbladder

When severe inflammation makes dissection challenging:

- acute cholecystitis
- empyema
- gangrene
- perforation
- Mirizzi syndrome
- Fibrotic rind
- Difficulty elevating
- Large impacted stone in infundibulum

Risk Factors for the Difficult Gallbladder

- Cholecystitis
  - Chronic
  - Thick-walled or contracted/shrunken gallbladder
  - >10 (multiple) episodes of biliary colic
  - Prior acute cholecystitis
  - Percutaneous cholecystostomy tube
- Acute
  - >72–96 hours since onset of symptoms
  - White blood cell count >18,000/lL
  - Palpable gallbladder
  - Gangrenous or perforated gallbladder
- Elderly (>65 years)
- Male gender
- Morbid obesity
- Mirizzi's syndrome or cholecystoenteric fistula
- Cirrhosis (especially with portal hypertension)
- Prior procedures
  - Open upper abdominal surgery
  - Previous attempt at cholecystectomy or partial cholecystectomy

DukeMedicine

Chronic cholecystitis

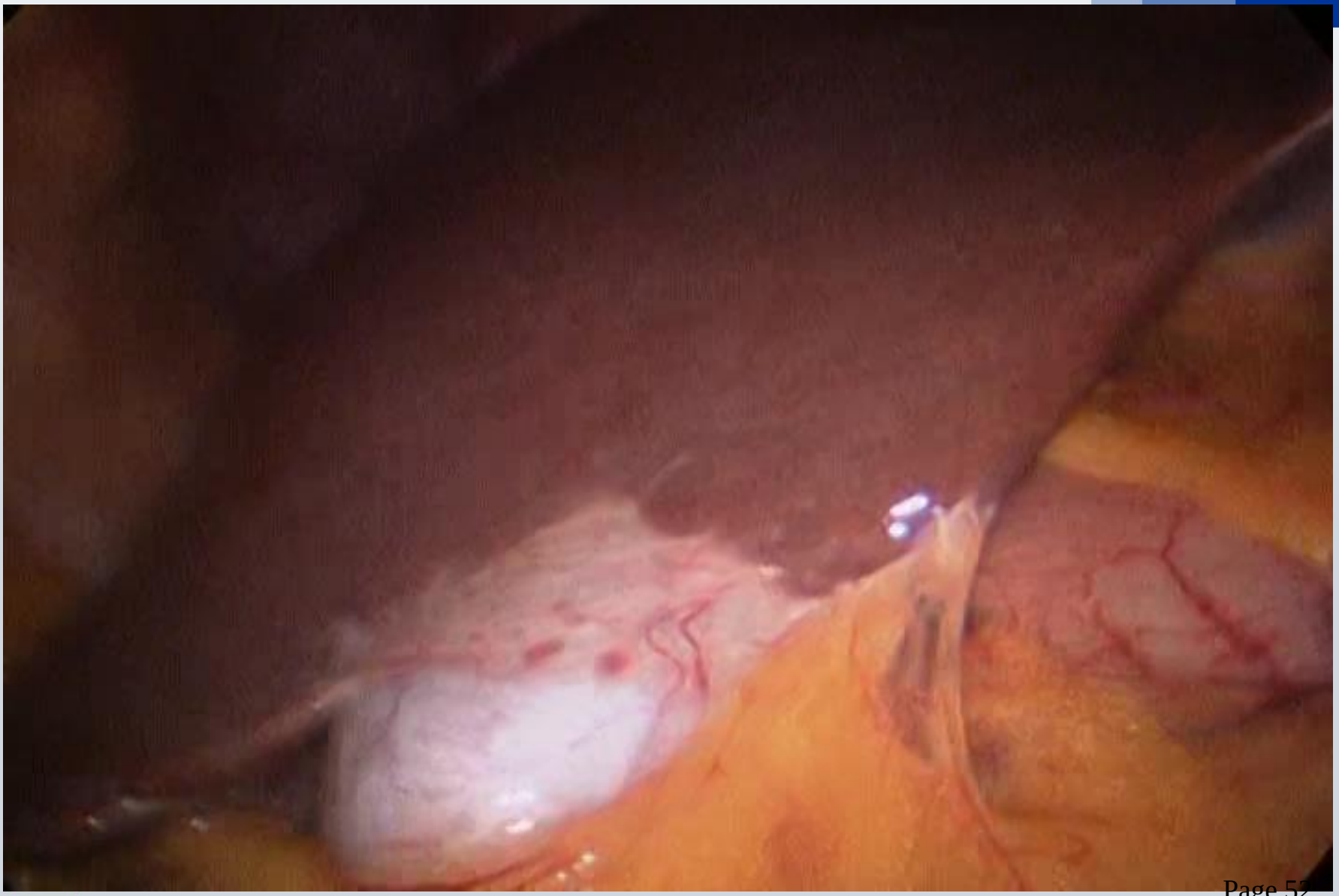

Chronic cholecystitis (severe) CONT

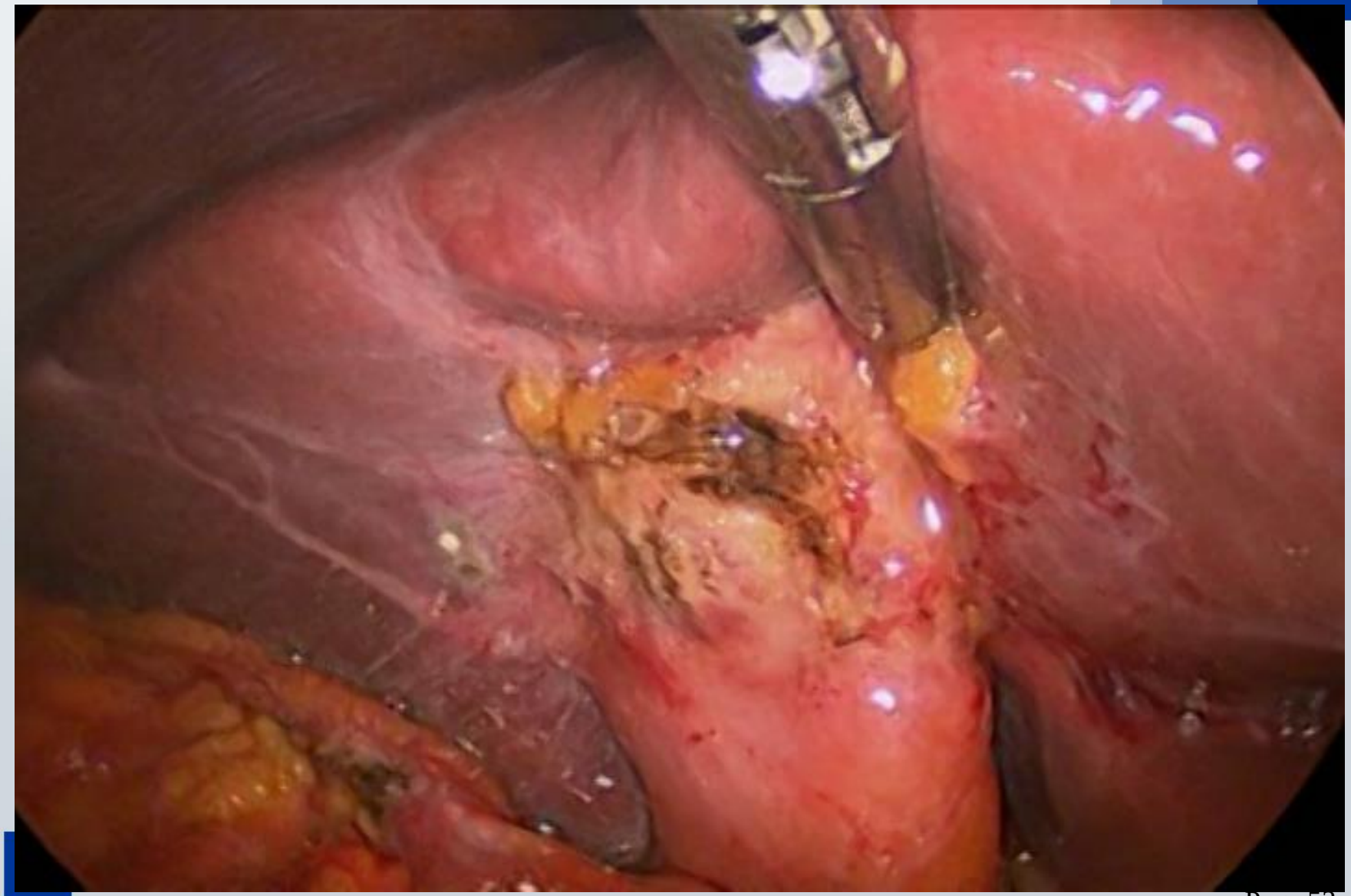

Intrahepatic GB (left-sided)